

# Advances in Glaucoma:

Gamma-Irradiated Sterile Cornea  
(VisionGraft®) Provides Safe, Effective  
Alternative for Glaucoma Procedures



## Advances in Glaucoma:

# Gamma-Irradiated Sterile Cornea (VisionGraft®) Provides Safe, Effective Alternative for Glaucoma Procedures

### INTRODUCTION

Glaucoma is rapidly becoming a major health care problem in the United States. It is estimated that more than 4.7 million Americans have glaucoma and, due to the rapid aging of the U.S. population, this number will likely increase in the coming years.<sup>1</sup> Moreover, the cost of glaucoma to the U.S. government, in terms of Social Security benefits, lost income tax revenues, and health care expenditures, is estimated to be over \$1.5 billion annually.<sup>2</sup>

Treatments to slow the progression of the disease are available. Traditional treatment for patients with “complicated glaucoma” involves a surgically implanted glaucoma drainage device. There are a number of drainage devices available to surgeons (see Figure 1.), and it is estimated that tens of thousands of devices are implanted in the U.S. every year.

Although these devices have proven to be useful in the management of complex glaucoma cases, many potential complications can result from their insertion, including erosion and exposure of the tube or device, as well as hypotony, choroidal problems, and hyphema.<sup>3</sup> To prevent tube erosion and other associated complications, most drainage devices are covered with a tissue allograft.<sup>4</sup> Common allograft materials may include donor sclera, pericardium, dura mater, and fascia

Figure 1.

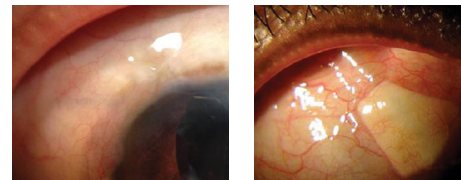
### Glaucoma Drainage Devices

- Molteno Implant (IOP Inc., Costa Mesa, CA)
- Baerveldt Tube Shunt (Abbott Medical Optics, AMO, Santa Ana, CA)
- Ahmed Glaucoma Valve (New World Medical, Rancho Cucamonga, CA)
- Krupin Slit Valve (Hood Laboratories, Pembroke, MA)

lata. However, the inability for surgeons to visualize tubes post-operatively through certain tissue coverings may pose a potential challenge for this method. Also, some patients feel that the overlying tissue may produce a noticeable “bump” or create an unpleasant appearance.

### A CLEAR ALTERNATIVE

Figure 3.

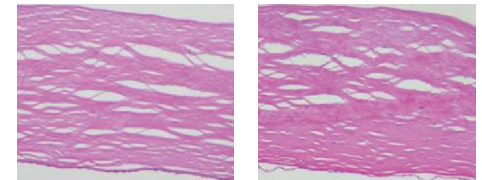


VisionGraft® Patch      Sclera Patch

Several studies show that using VisionGraft®, a sterile, gamma-irradiated cornea allograft made available by CorneaGen, may provide a safe and effective alternative for glaucoma procedures requiring allografts. In fact, one study, which reported on 150 patient outcomes using irradiated corneas in nonendothelial surgical applications, found that VisionGraft® was “suitable for any use where a clear human tissue is needed.”<sup>4</sup> In the study, which surveyed 19 surgeons who used 198 irradiated donor corneas in ocular surgery, researchers found that the pre- and post-operative impressions of the surgeons were positive, particularly in terms of ease of use, clarity, thickness, tensile strength, and suturing, as well as

epithelialization and biological incorporation.<sup>7</sup>

Figure 2.



Irradiated Cornea      Fresh Cornea

In a study that tested the optical properties of 20 donor corneas, researchers found that tissues sterilized with irradiation had pachymetry, deeper stromal histology (see Figure 2.), and ultrastructural characteristics comparable with non-irradiated tissues and should be suitable for such clinical applications as tectonic keratoplasty or to cover glaucoma drainage tubes.<sup>6</sup> Another study found that the clarity of the VisionGraft® provides the option of laser suture lysis to increase drainage post-operatively without the risk of releasable sutures or instrumentation within the eye. This is particularly important for non-valved devices, such as the Baerveldt tube shunt or the Molteno implant, because the VisionGraft® allows visualization (see Figure 3.) of the tube for selected suture removal depending on the intraocular pressure (IOP) level in the eye.<sup>8</sup>

### COMPARABLE TO FRESH CORNEAS

VisionGraft® sterile corneas are comparable to, and offer a number of advantages over, fresh corneas:

- Sterile gamma-irradiated corneas have similar thickness as fresh corneas and handling is identical.<sup>9</sup>
- The tissue does not require rehydration prior to surgery and is clear when implanted.
- Gamma-irradiation offers additional patient safety, compared to fresh corneas, and virtually eliminates the risk of bacterial or fungal disease.<sup>5</sup>

- A key benefit of the VisionGraft® cornea is the fact that gamma-irradiation has demonstrated the ability to deplete antigen-presenting cells transferred within the donor tissue; this reduces the likelihood of graft rejection by “preventing the direct sensitization.”<sup>10</sup>
- In addition to reducing immunogenicity, gamma-irradiation may reduce the allogenicity of the tissue used in anterior lamellar keratoplasty and keratoprosthesis procedures.<sup>11</sup>
- VisionGraft® offers a shelf life of two years at room temperature, a low erosion rate of 2.5%, and demonstrated positive clinical outcomes for up to 24 months.<sup>12</sup>

Studies have also demonstrated that VisionGraft® is easier to work with than other patch graft materials and provides better durability and tensile strength, and reduces or eliminates erosions. was no incidence of immune rejection, infection, significant opacification, or neovascularization of the donor tissues during the follow-up period.<sup>9</sup>

Lab testing on the VisionGraft® tissue included suture pull-through testing, which demonstrated comparable strength with that of fresh corneal tissue, histopathology studies that demonstrated normal collagen structure, and electron microscopy testing, which demonstrated similar mean interfibrillar distance and fibril diameter to that of non-irradiated fresh corneas.<sup>6</sup>

**A SOLUTION FOR SECONDARY CASES**

One of the most serious complications of glaucoma drainage implants is exposure of the drainage device due to erosion of the tube, which can lead to intraocular infection if not detected in a timely manner and corrected.<sup>7</sup> Nearly all cases of tube erosion require surgery at the site of exposure, and the most common method is to suture a patch graft over the area where the tube enters the anterior chamber.<sup>13</sup> Gamma-irradiated cornea tissue has been shown to be an effective solution in these cases, as well.

A recent multi-center retrospective analysis of 295 patients undergoing glaucoma drainage device (GDD) implantation

surgery, using a gamma-irradiated sterile cornea (VisionGraft®) as a primary patch graft, showed a significantly low rate of exposure.<sup>12</sup> Of the 319 eyes involved in the study, conducted from April 2009 - October 2012, only eight (2.5%) experienced graft-related tube erosion, with a median time of 13.3 months after surgery. The erosion rate for VisionGraft® is as much as six times lower when compared to other patch graft studies (see Figure 4.). The researchers concluded that because of the “high tensile strength and rigidity,” and other benefits of VisionGraft®, it “presents to be a safe and effective patch graft material.”

In another study, 10 patients with complicated glaucoma were treated with an irradiated allograft for coverage of a revised glaucoma tube shunt (five patients), tectonic support of a revised trabeculectomy flap (one patient), and coverage of subconjunctival prolene

sutures following a surgical iridoplasty (one patient).<sup>13</sup> The allografts were stable and biocompatible in all cases during the follow-up period (mean follow-up was 24 months), evidenced by maintained clarity of the corneal tissue, absence of clinical signs of immunologic rejection or ocular inflammation, and integrity of the sterile cornea and the conjunctiva over the graft (see Figure 5.). Allograft remained clear, results were satisfactory, and there were no complications reported during the follow-up period.

In some extreme secondary glaucoma procedures, the surgeon may be required to remove the tissue for diagnostic or interventional purposes. This can be problematic because pericardium often “grows” into the sclera, making revisions more difficult; on the other hand, the VisionGraft®, which is only 200-300 microns thick, peels back in a plane leaving all surrounding tissue intact. Additional

Figure 4.

Comparison: Graft-Related Tube Erosion Rates					
Study	Graft	Patient	Eye	Failure Rate	Failure Time
Pan	VisionGraft®	295	319	2.5%	12.3y +/- 7.2
Zalta	Dura	695	N/A	6.3%	5.8y +/- 3.8
	Sclera	1121	N/A	5.8%	2.7y +/- 1.9
Widgton	Glycerol	161	161	0%	1y
	Pericardium	101	101	15%	1y
Smith	Sclera	23	N/A	4.3%	15m
	Dura	18	N/A	5.6%	6m

Figure 5.

Comparison: Gamma Irradiation vs. Other Current Storage Methods for Cornea Tissue			
Properties	Irradiated Cornes	Glycerin Cornea	Cryopreservation
Sterile	Yes	No	No
Surgeon preparation	None required	Yes	Yes
Tissue quality	Very Good	Thicker, rubbery	Thinner
Storage- Duration Condition	2 years	5 years	2 weeks
	Room temp.	Room Temp	Refrigerated
Clarity	Clear	Inconsistent	Clear

alternative uses for VisionGraft® tissue in secondary glaucoma procedures include cases of scleral staphyloma, trabeculectomy, and inadvertent blebs.<sup>14</sup>

## CONCLUSION

In summary, the findings of the studies mentioned in this paper indicate that the sterile cornea allograft VisionGraft®, which has been utilized in over 70,000 glaucoma cases since its release in 2009, is a safe and effective alternative to traditional graft material for primary and secondary glaucoma surgical procedures.

## Synopsis

### Indications for Glaucoma Drainage Devices

- Prior failed glaucoma filtration surgery
- Need for better intraocular pressure control
- Refractory glaucomas, such as neovascular glaucoma, uveitic glaucoma, pediatric glaucoma, or traumatic glaucoma

### VisionGraft® Characteristics

- Gamma-irradiated corneal tissue
- Stable shelf-life at room temperature for two years
- No rehydration required / ready to use
- Clear when transplanted
- Durable, maintains shape with manipulation

### Benefits of Irradiation

- Reduces the likelihood of graft rejection
- No antigen-presenting cells transferred with donor tissue
- Eliminates risk of bacterial or fungal disease
- Does not change the tensile strength of corneal tissue

### Similar to Fresh Corneas

- Histopathology demonstrates normal collagen structure
- Similar mean interfibrillar distance and fibril diameter
- Thickness and handling (whole corneas)
- Comparable suture pull-through strength

### Surgeon Perspective of VisionGraft®

- Reduces or eliminates erosion
- Reduces re-operations
- Good re-epithelialization
- Provides a diagnostic window to the valve

### Patient Perspective of VisionGraft®

- Provides translucent outcome
- Reduces or eliminates the need for repeated surgeries to replace eroded tissue

### Alternative Solutions

- Sclera
- Glycerine-preserved cornea
- Pericardium
- Amnion

## REFERENCES

1. Form S-1/A Glaukos Corp. 2015; retrieved from <https://sec.report/Document/0001047469-15-005425/#a2225000zs-1a.htm>.
2. Chae JJ, Choi JS, Stark WJ, Elisseff JH. Extracellular Matrix Characterization of the Acellular Gamma- Irradiated Cornea.
3. Eye Bank Association of America. Statistical Report (2008). 2009. Available at: [http://www.restoresight.org/wp-content/uploads/2013/04/2012\\_Statistical\\_Report\\_FINAL-reduced-size-4-10.pdf](http://www.restoresight.org/wp-content/uploads/2013/04/2012_Statistical_Report_FINAL-reduced-size-4-10.pdf). Accessed July 15, 2013.
4. Weiss JL, Williams P, Lindrom RL, Doughman DJ. The use of tissue adhesive in corneal perforations. *Ophthalmology*. 1983; 90(6):610-616.
5. Izaguirre Roncal LB, Gonzalvo Ibanez FJ, Perez Olivan S, Sanchez Perez A, Brito Suarez C, Honrubia Lopez FM. [Conjunctival flaps in corneal perforations]. *Arch Soc Esp Oftalmol*. 2000; 75(12):825-829.
6. Rodriguez-Ares MT, Tourino R, Lopez-Valladares MJ, Gude F. Multilayer amniotic membrane transplantation in the treatment of corneal perforations. *Cornea*. 2004; 23(6):577-583.
7. Larsson S. Treatment of perforated corneal ulcer by autoplasmic scleral transplantation. *Br J Ophthalmol*. 1948; 32(1):54-57.
8. Parmar P, Salman A, Jesudasan CA. Visual outcome and corneal topography after eccentric "shaped" corneal grafts. *Cornea*. 2009; 28(4):379-384.
9. Shi W, Liu M, Gao H, Li S, Want T, Xie L. Penetrating keratoplasty with small-diameter and glycerin-cryopreserved grafts for eccentric corneal perforations. *Cornea*. 2009; 28(6):631-637.
10. King JH Jr, Townsend WM. The prolonged storage of donor corneas by glycerine dehydration. *Trans Am Ophthalmol Soc*. 1984; 82:106-110.
11. Utine CA, Tzu, JH, Akpek EK. Lamellar keratoplasty using gamma-irradiated corneal lenticules. *Am J Ophthalmol*. 2011; 151(1):170-174.
12. Heflin TH, Yoshida J, Zambrano A, Jun A, Meng H, Pan Q, Stark W, Daoud Y. Gamma-irradiated Sterile Cornea for use in Penetrating Keratoplasty: A Novel Approach.
13. Lawrence SD, Netland PA. Gamma-irradiated cornea allograft for glaucoma surgery. *J Glaucoma*. 2013 Jun-Jul; 22(5): 355-7.
14. Stevenson W, Cheng SF, Emami-Naeini P, Hua J, Paschalis EI, Dana R, Saban DR. Gamma-irradiation reduces the allogenicity of donor corneas. *Invest Ophthalmol Vis Sci*. 2012 Oct 1;53(11):7151-8.
15. Corrales G. Using VisionGraft® for Emergency Penetrating Keratoplasty. 2012; retrieved from <http://www.visiongraft.org/content/using-visiongraft%C2%AE-emergency-penetrating-keratoplasty>.
16. Sikder S, McCally RL, Engler C, Ward D, Jun AS. Evaluation of irradiated corneas using scatterometry and light and electron microscopy. *Cornea*. 2011; 30(5):503-507.
17. Akpek EK, Aldave AJ, Aquavella JV. The use of precut, γ-irradiated corneal lenticules in Boston type 1 keratoprosthesis implantation. *Am J Ophthalmol*. 2012 Sep;154(3):495-498.e1.